

RELIABILITY AND MEASUREMENT ERROR OF THE PROXIMAL, MEDIAL AND DISTAL PORTIONS OF THE VASTUS LATERALIS MUSCLE THICKNESS MEASURED WITH EXTENDED FIELD OF VIEW ULTRASONOGRAPHY

Bruno Rodrigues Arruda, André Luiz Conveniente Soares,
Ramon Franco Carvalho, and Paulo Sergio Chagas Gomes

*Institute of Physical Education and Sports, Laboratory Crossbridges,
Rio de Janeiro State University, Rio de Janeiro, Brazil*

Original scientific paper
DOI 10.26582/k.54.1.11

Abstract:

The image obtained by static ultrasonography (US), despite being a validated measure to identify muscle thickness (MT), has a visualization capacity limited by the size of the transducer. The extended field of view (EFOV) is a more recent technique of obtaining muscle images by the US, which allows observing MT over the entire length of the muscle. The purpose of the study was to determine the reliability and the intra- and inter-rater error of the MT measurement in the proximal, medial and distal portions of the vastus lateralis using the EFOV US. Twenty-five men (age = 24 ± 4 years) paid a visit to the laboratory. Two independent US technicians identified the anatomical landmarks and collected the images using EFOV US, with a 4 cm linear transducer, 10 MHz frequency and 6 cm image depth. After all collections, a third researcher codified the images, which were sent to two independent image raters. After a week, the images were shuffled, recoded and sent back to the same evaluators. The values of the typical error of the measurement, coefficient of variation and intraclass correlation coefficient intra and inter-rater ranged between 0.01 and 0.03 cm, 0.47 and 2.32%, 0.990 and 0.998, respectively, for the two evaluators. The Bland-Altman analysis indicated high agreement and homoscedastic error of all comparisons. The high reliability and low errors observed, less than the increments typically found in training studies, reveal the great potential for EFOV US to determine MT in different portions of the vastus lateralis muscle.

Key words: *Anatomy, Data accuracy, Hypertrophy, Lower extremity, Muscle tissue, Quadriceps muscle*

Introduction

Muscle thickness (MT) is commonly defined as the longitudinal distance between the superficial and deep aponeurosis (Hodson-Tole & Lai, 2019). MT is directly associated with the anatomical cross-sectional area and muscle volume (Franchi et al., 2018). Therefore, the MT measurement can be considered an important variable that allows monitoring the modifications resulting from different treatments such as resistance training (Schoenfeld et al., 2019), electrical stimulation (Devrimsel et al., 2019) and stretching routines (Lima et al., 2015).

Ultrasonography (US) is a valid method for determining MT when compared to computerized tomography (CT) and magnetic resonance imaging (MRI), gold standard methods (Dupont et al., 2001; Juul-Kristensen et al., 2000). Dupont et al. (2001) determined the validity of MT measurements using the US, compared to CT and MRI, showing corre-

lation coefficient values ranging between 0.88 and 0.99. US does not expose the subject to radiation such as CT (Sipilä & Suominen, 1993) and it is much cheaper than MRI and, therefore, more widely available in clinical and research settings (Lixandrão et al., 2014).

Static US has a limitation of visualizing only a smaller muscle area in a typical US scan, which is a function of the transducer size used (Ahtiainen et al., 2010). Lately, a new technique, the extended field-of-view (EFOV) US method, has gained popularity (Earp et al., 2015; Simpson et al., 2017; Soares et al., 2021). EFOV US allows image registration far beyond the simple size of the transducer since a continuous scan of the area of interest is registered by the rendering of sequential images processed by dedicated software for such. Therefore, a much larger muscle visualization area is possible in a single session (Scott et al., 2012).

The main advantage of EFOV US is the possibility of visualizing the proximal, medial and distal portions of a particular muscle, such as the vastus lateralis, enabling the identification of different portions, as has been shown in more recent studies (Oranchuk et al., 2020; Soares et al., 2021). It is also possible to evaluate other muscle architecture variables, such as fascicle length and angle, with no need to estimate with prediction equations (Ando et al., 2014). Another advantage is the possibility of visualizing aponeuroses in a non-linear way, reducing the chances of overestimating them (Pimenta et al., 2018).

For example, in resistance training studies, it is common to observe different adaptation magnitudes in muscle architecture at different muscle sites, such as the proximal, medial and distal portions (Earp et al., 2015; Ema et al., 2013; Mangine et al., 2018; Trindade et al., 2019). One cannot assume that absolute and relative measurement error is similar at different muscle portions. Thus, a reliable tool with high consistency of measurement is needed to monitor possible changes in different portions of the muscle of interest, such as in the case of selective muscle hypertrophy, as a result of some intervention.

Based on our group's recent yet unpublished systematic review with meta-analysis we observed that the vastus lateralis muscle is used most in resistance training studies, primarily when muscle thickness is assessed with US. Researchers have great interest in the vastus lateralis site, mainly due to the ease of performing the measurement. However, several of these studies use careless ways of performing this measurement. Practically none used the panoramic measurement and very few reported the error of such measurement to get accurate values. This is particularly when we are often looking at small changes in muscle hypertrophy.

Therefore, the study aimed to determine the reliability and measurement error of the proximal, medial and distal portions of the vastus lateralis MT measured by EFOV US. The secondary aim was to determine the difference in absolute and relative MT errors in different portions of the vastus lateralis. The results and the protocol proposed in the present study may provide a basis for determining MT in different muscle portions, facilitating and standardizing identifications of possible measurement changes.

Materials and Methods

Study Sample

The study included twenty-five young male university students (age = 24 ± 4 years; body mass = 76.4 ± 11.6 kg; stature = 176.0 ± 7.0 cm), apparently healthy according to the PAR-Q questionnaire. All volunteers were informed about the risks, procedures, purpose of the study and signed an informed

consent form before starting the procedures. The Research Ethics Committee of Hospital Universitário Pedro Ernesto approved this study under protocol number 3.957.153 and the manuscript was performed following the ethical standards of the Helsinki Declaration.

Study design

Participants made one visit to the laboratory under the recommendation of not performing any physical activity that required vigorous physical effort 24 hours before collecting the images. Upon entering the laboratory, all volunteers were at rest for 20 minutes. Later, an experienced researcher performed anthropometric measurements to characterize the sample.

Two independent US technicians previously trained to perform the measurements collected the ultrasound images separately. At their moment of data collection, the US technicians performed the markings of the anatomical points to set the positioning of the guide rail. Three images were collected of each subject and those that best presented the clarity and sharpness of the MT were selected for further analysis. Once the first finished collecting the images, all markings were erased so that the second US technician could repeat the procedure not influenced by the previous one. Each US technician took an average of 10 minutes to perform anatomical landmarks, position the guide rail and start collecting the images.

A third researcher who did not participate in the evaluation of the images codified all of them and distributed them to two independent image raters to determine the measurements of MTs. After seven days, the third researcher shuffled and recoded the images and forwarded them to the image raters for further measures. The third researcher also discarded low-quality, cloudy and non-linear images.

Identification of anatomical landmarks

While the subject stood standing, several anatomical landmarks were identified, always on the right side of the body. A guide rail specifically developed to assist in the displacement of the linear transducer, with an interior of 13 centimeters, would be later positioned in the lateral region of the thigh. Before placing the guide rail, anatomical landmarks were determined as follows: the upper edge of the iliac crest, the upper edge of the greater trochanter of the femur, the upper limit of the lateral epicondyle of the tibia and the midpoint of the upper edge of the patella. After marking the anatomical points, the proximal region equivalent to 40% was identified between the upper edge of the greater trochanter of the femur and the upper limit of the lateral epicondyle of the tibia, as shown in Figure 1a.

Acquisition of ultrasound images

The volunteer was positioned on a stretcher, with the right knee supported by Styrofoam, in the supine position, generating a slight flexion and preventing the rotation of the knee. An anthropometer positioned between the upper edge of the iliac crest and the midpoint of the upper edge of the patella helped the positioning of the track, pre-setting an angle of 15° with the sagittal plane, as shown in Figure 1b. A linear transducer was coated with a water-based conductive gel (Multigel, Minas Gerais, Brazil) and moved longitudinally and steadily from proximal to distal, generating a 13 centimeters panoramic image. Two independent US technicians identified and marked the external anatomical landmarks and made three images.

The images were collected using an ultrasound device (GE Logiq e, GE Healthcare, USA), in B mode, using proprietary software (GE LogicView, GE Healthcare, USA) with a 4 centimeters linear transducer and a frequency of 10 MHz, with 6 centimeters image depth.

Determination of muscle thickness

Two image raters independently measured proximal (MTp), medial (MTm) and distal muscle thickness (MTd) to determine the reliability and measurement error. MTp was defined as the longitudinal distance between the deep and superfi-

cial aponeuroses on the left edge. MTm was the distance between the deep and superficial aponeuroses immediately to the center of the vastus lateralis muscle. MTd was the longitudinal distance between the deep and superficial aponeuroses on the right edge, as shown in Figure 1c.

Image analysis, editing and investigation of the variables of interest were carried out using an open-source image processing program (ImageJ, ver. 1.50f, National Institutes of Health, USA). Image J routine to assess the images followed the recommendations by Soares et al. (2021).

Statistical analysis

The normality of the data distribution was tested using the Shapiro-Wilk statistics. The typical error of the measurement (TEM) and the coefficient of variation (CV) was calculated as suggested by Hopkins (2000) and Atkinson & Nevill (1998), respectively.

Reliability was determined with an intraclass correlation coefficient (ICC) using a two-way model, mixed-effects, single measures and absolute agreement, based on the forms defined by McGraw & Wong (1996) and the model suggested by Shrout & Fleiss (1979). A Bland-Altman analysis was used to assess the degree of agreement of the measures followed by the Pearson correlation coefficient (r) values between the difference and mean of the pairs of measures (Bland & Altman, 1986).

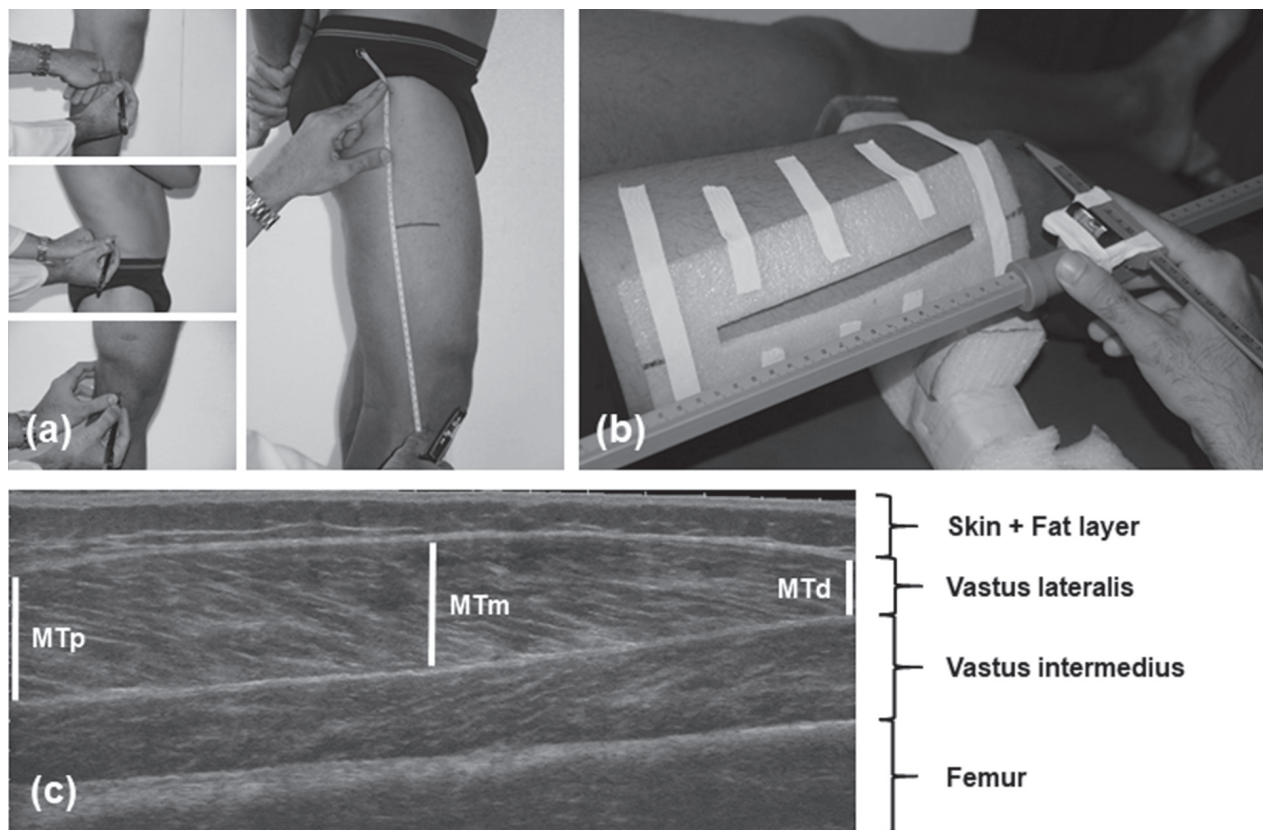


Figure 1. Marking of anatomical landmarks (a); positioning of the guide rail (b); panoramic ultrasound image with measurements of muscle thickness in the proximal (MTp), medial (MTm) and distal (MTd) portions (c).

One-way ANOVA with Bonferroni *post hoc* test was used to determine if there was a difference in the general distribution of the MT error in the different portions of the vastus lateralis muscle from their absolute differences and relative differences by individual CVs.

Commercially available statistical packages Statistical Package for the Social Sciences for Windows, version 21.0 (IBM SPSS Inc., Chicago, IL, USA) and GraphPad Prism for Windows, version 7.0 (GraphPad Software Inc., San Diego, CA, USA) were used for the analyses. All statistical analyses were tested at the 0.05 level of confidence.

Results

The Shapiro-Wilk test demonstrated no departure from normality for all portions of the vastus lateralis muscle analyzed by image raters and US technicians.

Tables 1 and 2 show the reliability and error analysis of the intra-rater measurement of the vastus lateralis in the proximal, medial and distal portions determined by image raters 1 and 2, respectively, for both US technicians.

Table 3 shows the reliability and error values observed in inter-rater analysis and between US technicians’ measurements of the proximal, medial and distal portions of the vastus lateralis muscle.

The Bland-Altman analysis showed high agreement between the pairs of measures and characteristics of homoscedastic error for all combinations,

as shown in Table 4. Pearson’s r values ranged from |0.006 to 0.500|.

Figure 2 shows the difference in the general distribution of the MT error in the different portions of the vastus lateralis muscle from their relative differences (p=0.000), but not between absolute differences (p=0.301). There was a significant difference between MTp and MTm errors against MTd (p=0.000), but not between MTp and MTm (p=1.000) from their relative differences.

Discussion and conclusions

Previous studies have shown that the vastus lateralis MT measurements obtained through the static US showed high reliability (Ema et al., 2013; Franchi et al., 2018; Lima & Oliveira, 2013; Mangine et al., 2018; Raj et al., 2012; Ruas et al., 2017). Several measurements will be necessary if the evaluator wishes to observe the MT along the muscle length (Ema et al., 2013; Mangine et al., 2018). EFOV US reduces the number of collections, speeds up the evaluation process and allows a single image to observe the proximal, medial and distal portions of the muscle of interest (Oranchuk et al., 2020; Soares et al., 2021).

The current literature shows high ICC values for MT of the vastus lateralis muscle, ranging between 0.88 to 0.99 in the studies that used static US (Franchi et al., 2018; Mangine et al., 2018) and 0.94 to 0.96 for the EFOV US method (Oranchuk et al., 2020; Soares et al., 2021). The present study

Table 1. Intra-rater analysis of test and retest for the proximal, medial and distal portions of the vastus lateralis muscle thickness (MT) for ultrasonography technician 1.

	MT Portion	Mean ± SD (cm)	TEM (cm)	CV (%)	ICC (p)
Image rater 1	Proximal	2.21 ± 0.37	0.02	0.99	0.995 (0.000)
	Medial	2.21 ± 0.31	0.03	1.10	0.991 (0.000)
	Distal	1.37 ± 0.43	0.03	1.76	0.996 (0.000)
Image rater 2	Proximal	2.23 ± 0.35	0.02	0.76	0.996 (0.000)
	Medial	2.23 ± 0.30	0.02	0.63	0.995 (0.000)
	Distal	1.40 ± 0.43	0.01	0.90	0.998 (0.000)

CV: coefficient of variation; ICC: intraclass correlation coefficient; SD: standard deviation; TEM: typical error of measurement.

Table 2. Intra-rater analysis of test and retest for the proximal, medial and distal portions of the vastus lateralis muscle thickness (MT) for ultrasonography technician 2.

	MT Portion	Mean ± SD (cm)	TEM (cm)	CV (%)	ICC (p)
Image rater 1	Proximal	2.20 ± 0.37	0.03	0.98	0.995 (0.000)
	Medial	2.24 ± 0.39	0.03	1.03	0.996 (0.000)
	Distal	1.37 ± 0.38	0.03	1.61	0.994 (0.000)
Image rater 2	Proximal	2.20 ± 0.36	0.02	0.47	0.998 (0.000)
	Medial	2.25 ± 0.39	0.02	0.73	0.997 (0.000)
	Distal	1.39 ± 0.38	0.02	0.71	0.998 (0.000)

CV: coefficient of variation; ICC: intraclass correlation coefficient; SD: standard deviation; TEM: typical error of measurement.

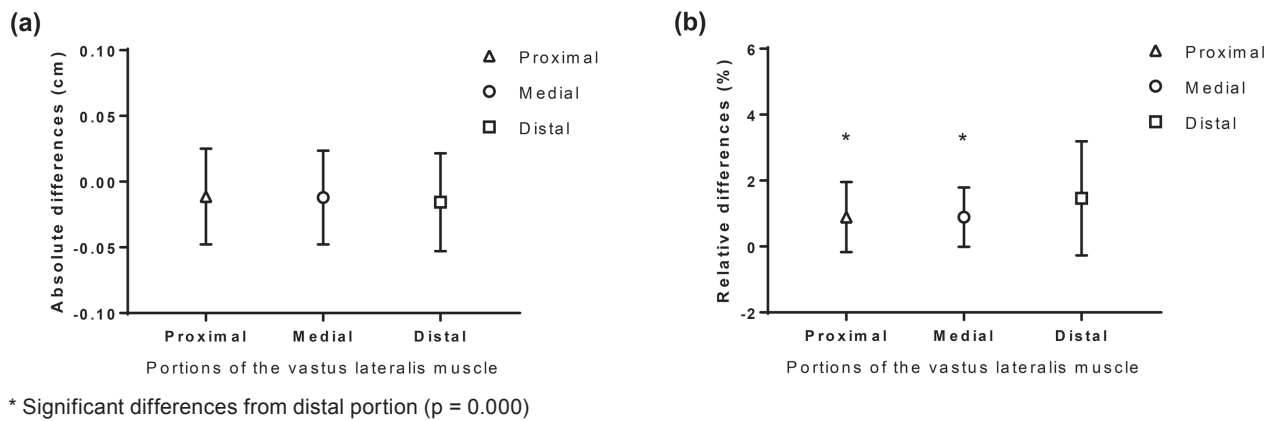


Figure 2. Mean and standard deviation of the general distribution of the muscle thickness error in the different portions of the vastus lateralis muscle from their absolute (a) and relative (b) differences.

showed ICC values above 0.99 for all testing conditions, indicating results slightly higher than those previously observed. Although the ICC is one of the most commonly used statistical models to observe reliability, it is not sensitive to systematic changes in measurement since it has lower results with a more homogeneous sample (Atkinson & Nevill, 1998). Thus, it must be accompanied by other analyzes such as Bland-Altman and TEM. In the present investigation, TEM ranged from 0.01 to 0.03 centimeters. The absolute errors of the measurements were lower than the previous studies reviewed (Lima & Oliveira, 2013; Oranchuk et al., 2020; Soares et al., 2021), as shown in Table 5.

Also, the Bland-Altman analysis showed a high agreement between the pairs of measures considering the agreement limit of 1.96 standard deviations. This analysis demonstrated a low absolute difference between the measurements made by image raters 1 and 2 in the images collected by both US technicians, as shown in Table 4. Pearson's low r values ($r \leq 0.5$) between the mean and the intra-subject difference indicated homoscedastic error for all pair comparisons. Our laboratory experience has shown that strict adherence to the technical recommendations for identifying anatomical landmarks and the constant practice of measurements resulting from several repetitions during the learning process

has improved the quality of the results obtained in low error and high reliability.

In previously published studies, coefficient of variation (CV) values showed that different portions of the vastus lateralis muscle showed percentages varying between 1.5% to 3.8% (Ema et al., 2013; Lima & Oliveira, 2013). The present study observed similar values where CVs varied between 0.47% to 2.32% for all US technicians and image raters tested. However, it is possible that the CV showed in the present study is not necessarily related to the use of EFOV US. One possible explanation may be related to methodological care and the previous definition of the measurement sites for the present study's proximal, medial and distal portions. Using a fixed position in the image, the evaluators could repeat the second assessment at the almost exact location or very close to it.

Despite the present study results showing low percentage changes in CV, the distal portions showed the highest values. Such a condition was observed in both intra- and inter-rater comparisons. This phenomenon can be explained due to the lower absolute mean values of MTd than MTp and MTm. Thus, the identical absolute variation in the MT measurement represents a distinct percentage variation in the different portions, thus having a more significant relative impact in the distal region due

Table 3. Inter-rater analysis (minimum and maximum) for the proximal, medial and distal portions of the vastus lateralis muscle thickness (MT) for ultrasonography technician 1 (T1) and ultrasonography technician 2 (T2).

	MT Portion	Mean ± SD (cm)	TEM (cm)	CV (%)	ICC (P)
T1	Proximal	2.22 ± 0.36	0.02 - 0.03	1.03 - 1.24	0.990 - 0.993 (0.000)
	Medial	2.20 ± 0.30	0.02 - 0.03	0.66 - 0.98	0.990 - 0.996 (0.000)
	Distal	1.39 ± 0.43	0.03 - 0.03	1.59 - 2.32	0.991 - 0.995 (0.000)
T2	Proximal	2.21 ± 0.36	0.03 - 0.03	0.60 - 0.93	0.994 - 0.996 (0.000)
	Medial	2.25 ± 0.39	0.03 - 0.03	0.88 - 1.08	0.994 - 0.995 (0.000)
	Distal	1.38 ± 0.38	0.02 - 0.03	1.23 - 1.40	0.994 - 0.996 (0.000)

CV: coefficient of variation; ICC: intraclass correlation coefficient; SD: standard deviation; TEM: typical error of measurement.

Table 4. Results of the Bland-Altman analysis for muscle thickness measurements of the vastus lateralis muscle in different portions.

Comparisons	US Technician 1		US Technician 2	
	Bias ± SD Bias (cm)	95% LA (cm)	Bias ± SD Bias (cm)	95% LA (cm)
Proximal Portion				
IR 1 (day 1x2)	0.013 ± 0.034	-0.055 – 0.081	0.004 ± 0.036	-0.066 – 0.074
IR 2 (day 1x2)	-0.004 ± 0.033	-0.070 – 0.062	-0.004 ± 0.025	-0.053 – 0.044
IR 1x2 (day 1)	-0.014 ± 0.045	-0.102 – 0.075	-0.010 ± 0.026	-0.061 – 0.041
IR 1x2 (day 2)	-0.030 ± 0.035	-0.099 – 0.038	-0.018 ± 0.027	-0.071 – 0.034
IR 1x2 (day 1x2)	-0.018 ± 0.041	-0.098 – 0.063	-0.014 ± 0.029	-0.071 – 0.042
IR 1x2 (day 2x1)	-0.026 ± 0.046	-0.117 – 0.064	-0.014 ± 0.035	-0.082 – 0.054
Medial Portion				
IR 1 (day 1x2)	-0.009 ± 0.042	-0.092 – 0.074	-0.011 ± 0.036	-0.080 – 0.059
IR 2 (day 1x2)	-0.002 ± 0.029	-0.060 – 0.056	-0.003 ± 0.033	-0.062 – 0.068
IR 1x2 (day 1)	-0.020 ± 0.033	-0.084 – 0.045	-0.022 ± 0.035	-0.092 – 0.047
IR 1x2 (day 2)	-0.013 ± 0.025	-0.062 – 0.037	-0.008 ± 0.038	-0.083 – 0.067
IR 1x2 (day 1x2)	-0.022 ± 0.039	-0.098 – 0.054	-0.019 ± 0.039	-0.096 – 0.057
IR 1x2 (day 2x1)	-0.011 ± 0.031	-0.072 – 0.051	-0.012 ± 0.041	-0.091 – 0.068
Distal Portion				
IR 1 (day 1x2)	-0.016 ± 0.037	-0.088 – 0.057	0.009 ± 0.040	-0.088 – 0.071
IR 2 (day 1x2)	-0.016 ± 0.020	-0.055 – 0.023	-0.001 ± 0.022	-0.042 – 0.044
IR 1x2 (day 1)	-0.021 ± 0.043	-0.105 – 0.062	-0.020 ± 0.039	-0.097 – 0.056
IR 1x2 (day 2)	-0.022 ± 0.039	-0.099 – 0.055	-0.010 ± 0.035	-0.080 – 0.059
IR 1x2 (day 1x2)	-0.038 ± 0.044	-0.124 – 0.049	-0.019 ± 0.030	-0.078 – 0.040
IR 1x2 (day 2x1)	-0,006 ± 0,042	-0,089 - 0,077	-0,012 ± 0,038	-0,085 - 0,062

IR: image rater; LA: limits of agreement; SD: standard deviation; US: ultrasonography.

Table 5. Reliability and measurement error of the vastus lateralis muscle thickness (MT) using static or extended-field-of-view (EFOV) ultrasonography of the current and previous studies.

Source	n (M:W)	Age in years Mean ± SD	Scanning Method	Condition	Statistical Index
Current study	25 (25:0)	24 ± 4	EFOV	Intra-rater Inter-rater	ICC = 0.991-0.998; CV = 0.47-1,76%; TEM = 0.01-0.03 cm ICC = 0.990-0.996; CV = 0.60-2,32%; TEM = 0.02-0.03 cm
Soares et al. (2021)	12 (12:0)	24 ± 6	EFOV	Intra-rater	ICC = 0.964; CV = 2.93%; TEM = 0.07 cm
Oranchuck et al. (2020)	26 (26:0)	29 ± 5	EFOV	Intra-rater	ICC = 0.94-0.96; CV = 2,4-3,8%; TEM = 0.15-0.26 cm
Magine et al. (2018)	10 (10:0)	25 ± 3	Static	Inter-rater	ICC = 0.88-0.92; SEM = 0.15-0.39 cm
Franchi et al. (2017)	9 (9:0)	24 ± 2	Static	Intra-rater	ICC = 0.99; SEM = 1.65%
Ruas et al. (2017)	10 (10:0)	23 ± 2	Static	Intra-rater	ICC = 0.97; SEM = 0.10 cm
Ema et al. (2013)	10 (10:0)	22 ± 2	Static	Intra-rater	ICC = 0.976-0.991; CV = 1.5-2.1%
Lima et al. (2013)	14 (4:10)	22 ± 2	Static	Intra-rater	ICC = 0.95-0.97; CV = 3.12-3.84%; TEM = 0.10-0.11 cm
Raj et al. (2012)	21 (11:10)	68 ± 5	Static	Intra-rater	ICC = 0.96

CV: coefficient of variation, ICC: intraclass correlation coefficient, SEM: standard error of measurement, TEM: typical error of measurement.

to the proportionality of the measurement. This hypothesis is reinforced by observing similar absolute differences, but not of relative differences in the three portions of the MT, as shown in Figure 2. TEMs and distal CVs in the present study continued to be lower or similar to those observed in the literature (Ema et al., 2013; Oranchuk et al., 2020).

The current study analyzed reliability and intra- and inter-rater error of MTp, MTm and MTd and showed high reliability ($ICC \geq 0.990$ and $p = 0.000$) and low measurement errors ($CV \leq 2.32\%$). Thus, it is suggested that EFOV US may be precise enough to identify muscle hypertrophy, considering that knee extension training studies showed average increments of 8 to 10% (Ema et al., 2013; Guilhem et al., 2013) in the vastus lateralis MT, which results superior to the measurement errors observed here.

The high reliability of the intra- and inter-rater MT and low error (absolute and relative) of the

measurement, smaller than those typically found in training studies, indicate a great potential for determining the MT. Therefore, it is suggested that from a single scan, the EFOV US method presented here may be an ideal and practical inexpensive way to monitor sectorial adaptations of the vastus lateralis muscle resulting from resistance training, electrical stimulation and stretching routine. However, the present study analyzed only a single muscle.

It is suggested that further studies be carried out to determine the reliability and error of the measurement of other muscles or muscle groups due to anatomical differences. There is also a need to investigate the sensibility of the proposed technique in assessing small MT changes in a training study comparing the US measurements with those provided by MRI, current the golden standard and very high cost. This study is already underway in our Laboratory.

References

- Ahtiainen, J. P., Hoffren, M., Hulmi, J. J., Pietikäinen, M., Mero, A. A., Avela, J., & Häkkinen, K. (2010). Panoramic ultrasonography is a valid method to measure changes in skeletal muscle cross-sectional area. *European Journal of Applied Physiology*, *108*(2), 273–279. <https://doi.org/10.1007/s00421-009-1211-6>
- Ando, R., Taniguchi, K., Saito, A., Fujimiya, M., Katayose, M., & Akima, H. (2014). Validity of fascicle length estimation in the vastus lateralis and vastus intermedius using ultrasonography. *Journal of Electromyography and Kinesiology*, *24*(2), 214–220. <https://doi.org/10.1016/j.jelekin.2014.01.003>
- Atkinson, G., & Nevill, A. M. (1998). Statistical methods for assessing measurement error (reliability) in variables relevant to sports medicine. *Sports Medicine*, *26*(4), 217–238. <https://doi.org/10.2165/00007256-199826040-00002>
- Bland, J. M., & Altman, D. G. (1986). Statistical methods for assessing agreement between two methods of clinical measurement. *The Lancet*, *327*(8476), 307–310. [https://doi.org/10.1016/S0140-6736\(86\)90837-8](https://doi.org/10.1016/S0140-6736(86)90837-8)
- Devrimsel, G., Metin, Y., & Beyazal, M. S. (2019). Short-term effects of neuromuscular electrical stimulation and ultrasound therapies on muscle architecture and functional capacity in knee osteoarthritis: a randomized study. *Clinical Rehabilitation*, *33*(3), 418–427. <https://doi.org/10.1177/0269215518817807>
- Dupont, A. C., Sauerbrei, E. E., Fenton, P. V., Shragge, P. C., Loeb, G. E., & Richmond, F. J. R. (2001). Real-time sonography to estimate muscle thickness: Comparison with MRI and CT. *Journal of Clinical Ultrasound*, *29*(4), 230–236. <https://doi.org/10.1002/jcu.1025>
- Earp, J. E., Newton, R. U., Cormie, P., & Blazevich, A. J. (2015). Inhomogeneous quadriceps femoris hypertrophy in response to strength and power training. *Medicine and Science in Sports and Exercise*, *47*(11), 2389–2397. <https://doi.org/10.1249/MSS.0000000000000669>
- Ema, R., Wakahara, T., Miyamoto, N., Kanehisa, H., & Kawakami, Y. (2013). Inhomogeneous architectural changes of the quadriceps femoris induced by resistance training. *European Journal of Applied Physiology*, *113*(11), 2691–2703. <https://doi.org/10.1007/s00421-013-2700-1>
- Franchi, M. V., Longo, S., Mallinson, J., Quinlan, J. I., Taylor, T., Greenhaff, P. L., & Narici, M. V. (2018). Muscle thickness correlates to muscle cross-sectional area in the assessment of strength training-induced hypertrophy. *Scandinavian Journal of Medicine and Science in Sports*, *28*(3), 846–853. <https://doi.org/10.1111/sms.12961>
- Guilhem, G., Cornu, C., Maffiuletti, N. A., & Guével, A. (2013). Neuromuscular adaptations to isoload versus isokinetic eccentric resistance training. *Medicine and Science in Sports and Exercise*, *45*(2), 326–335. <https://doi.org/10.1249/MSS.0b013e31826e7066>
- Hodson-Tole, E. F., & Lai, A. K. M. (2019). Ultrasound-derived changes in thickness of human ankle plantar flexor muscles during walking and running are not homogeneous along the muscle mid-belly region. *Scientific Reports*, *9*(1), 15090. <https://doi.org/10.1038/s41598-019-51510-4>
- Hopkins, W. G. (2000). Measures of reliability in sports medicine and science. *Sports Medicine*, *30*(1), 1–15. <https://doi.org/10.2165/00007256-200030010-00001>
- Juul-Kristensen, B., Bojsen-Møller, F., Holst, E., & Ekdahl, C. (2000). Comparison of muscle sizes and moment arms of two rotator cuff muscles measured by ultrasonography and magnetic resonance imaging. *European Journal of Ultrasound*, *11*(3), 161–173. [https://doi.org/10.1016/S0929-8266\(00\)00084-7](https://doi.org/10.1016/S0929-8266(00)00084-7)

- Lima, K. M. M., Carneiro, S. P., Alves, D. S., Peixinho, C. C., & Oliveira, L. F. (2015). Assessment of muscle architecture of the biceps femoris and vastus lateralis by ultrasound after a chronic stretching program. *Clinical Journal of Sport Medicine*, 25(1), 55–60. <https://doi.org/10.1097/JSM.0000000000000069>
- Lima, K. M. M., & Oliveira, L. F. (2013). Confiabilidade das medidas de arquitetura do músculo vasto lateral pela ultrassonografia. *Motriz: Revista de Educação Física*, 19(1), 217–223. <https://doi.org/10.1590/s1980-65742013000100022>
- Lixandrão, M. E., Ugrinowitsch, C., Bottaro, M., Chacon-Mikahil, M. P. T., Cavaglieri, C. R., Min, L. L., De Souza, E. O., Laurentino, G. C., & Libardi, C. A. (2014). Vastus lateralis muscle cross-sectional area ultrasonography validity for image fitting in humans. *Journal of Strength and Conditioning Research*, 28(11), 3293–3297. <https://doi.org/10.1519/JSC.0000000000000532>
- Mangine, G. T., Redd, M. J., Gonzalez, A. M., Townsend, J. R., Wells, A. J., Jajtner, A. R., Beyer, K. S., Boone, C. H., La Monica, M. B., Stout, J. R., Fukuda, D. H., Ratamess, N. A., & Hoffman, J. R. (2018). Resistance training does not induce uniform adaptations to quadriceps muscles. *PLoS ONE*, 13(8), e0198304. <https://doi.org/10.1371/journal.pone.0198304>
- McGraw, K. O., & Wong, S. P. (1996). Forming inferences about some intraclass correlation coefficients. *Psychological Methods*, 1(1), 30–46. <https://doi.org/10.1037/1082-989X.1.1.30>
- Oranchuk, D. J., Nelson, A. R., Storey, A. G., & Cronin, J. B. (2020). Variability of regional quadriceps architecture in trained men assessed by B-mode and extended-field-of-view ultrasonography. *International Journal of Sports Physiology and Performance*, 15(3), 430–436. <https://doi.org/10.1123/ijsp.2019-0050>
- Pimenta, R., Blazevich, A. J., & Freitas, S. R. (2018). Biceps femoris long-head architecture assessed using different sonographic techniques. *Medicine and Science in Sports and Exercise*, 50(12), 2584–2594. <https://doi.org/10.1249/MSS.0000000000001731>
- Raj, I. S., Bird, S. R., & Shield, A. J. (2012). Reliability of ultrasonographic measurement of the architecture of the vastus lateralis and gastrocnemius medialis muscles in older adults. *Clinical Physiology and Functional Imaging*, 32(1), 65–70. <https://doi.org/10.1111/j.1475-097X.2011.01056.x>
- Ruas, C. V., Pinto, R. S., Lima, C. D., Costa, P. B., & Brown, L. E. (2017). Test-retest reliability of muscle thickness, echo-intensity and cross sectional area of quadriceps and hamstrings muscle groups using B-mode ultrasound. *International Journal of Kinesiology and Sports Science*, 5(1), 37–41. <https://doi.org/10.7575/aiac.ijks.v.5n.1p.35>
- Schoenfeld, B. J., Contreras, B., Krieger, J., Grgic, J., Delcastillo, K., Belliard, R., & Alto, A. (2019). Resistance training volume enhances muscle hypertrophy but not strength in trained men. *Medicine and Science in Sports and Exercise*, 51(1), 94–103. <https://doi.org/10.1249/MSS.0000000000001764>
- Scott, J. M., Martin, D. S., Ploutz-Snyder, R., Caine, T., Matz, T., Arzeno, N. M., Buxton, R., & Ploutz-Snyder, L. (2012). Reliability and validity of panoramic ultrasound for muscle quantification. *Ultrasound in Medicine and Biology*, 38(9), 1656–1661. <https://doi.org/10.1016/j.ultrasmedbio.2012.04.018>
- Shrout, P. E., & Fleiss, J. L. (1979). Intraclass correlations: uses in assessing rater reliability. *Psychological Bulletin*, 86(2), 420–428. <https://doi.org/10.1037/0033-2909.86.2.420>
- Simpson, C. L., Kim, B. D. H., Bourcet, M. R., Jones, G. R., & Jakobi, J. M. (2017). Stretch training induces unequal adaptation in muscle fascicles and thickness in medial and lateral gastrocnemii. *Scandinavian Journal of Medicine and Science in Sports*, 27(12), 1597–1604. <https://doi.org/10.1111/sms.12822>
- Sipilä, S., & Suominen, H. (1993). Muscle ultrasonography and computed tomography in elderly trained and untrained women. *Muscle and Nerve*, 16(3), 294–300. <https://doi.org/10.1002/mus.880160309>
- Soares, A. L. C., Nogueira, F. S., & Gomes, P. S. C. (2021). Assessment methods of vastus lateralis muscle architecture using panoramic ultrasound: a new approach, test-retest reliability and measurement error. *Brazilian Journal of Kinanthropometry and Human Performance*, 23, e76402. <https://doi.org/10.1590/1980-0037.2021v23e76402>
- Trindade, T. B., Prestes, J., Neto, L. O., Medeiros, R. M. V., Tibana, R. A., de Sousa, N. M. F., Santana, E. E., Cabral, B. G. A. T., Stone, W. J., & Dantas, P. M. S. (2019). Effects of pre-exhaustion versus traditional resistance training on training volume, maximal strength and quadriceps hypertrophy. *Frontiers in Physiology*, 10, 1424. <https://doi.org/10.3389/fphys.2019.01424>

Submitted: July 8, 2021

Accepted: May 10, 2022

Published Online First: May 26, 2022

Correspondence to:

Paulo Sergio Chagas Gomes, Ph.D.

Institute of Physical Education and Sports

State University of Rio de Janeiro

Rua São Francisco Xavier, nº 524

8th Floor, Bloco F, Room 8104

Rio de Janeiro, RJ, CEP

Brasil, 20550-900

E-mail: Paulo.gomes@uerj.br